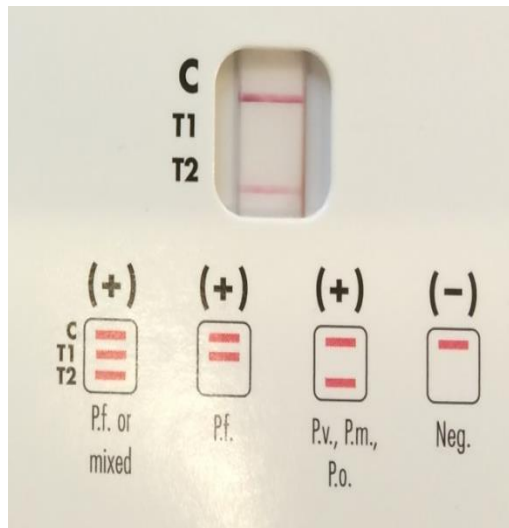


Imported malaria from Africa with false negative rapid diagnostic test for *P. falciparum* due to deletion of the histidine-rich protein 2 gene

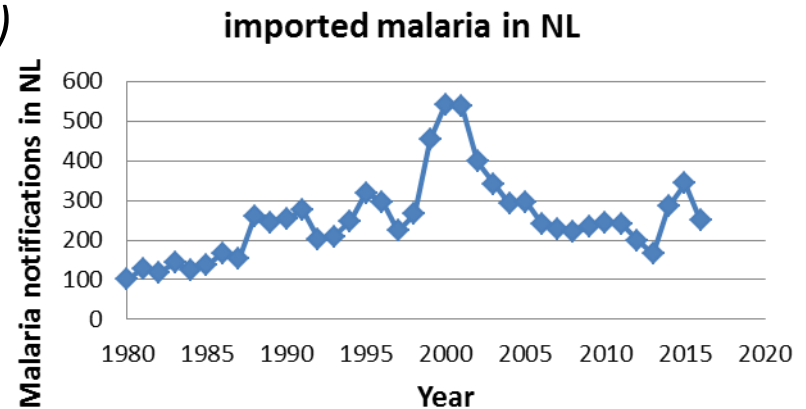
Aldert Bart¹, Nienke Verhaar¹, Jarne van Hattem¹, Michèle van Vugt², Godelieve de Bree², Tom van Gool¹



¹Department of Medical Microbiology and
²Department of Internal Medicine,
Academic Medical Center, Amsterdam, The
Netherlands

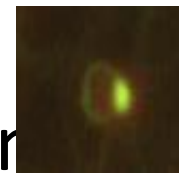
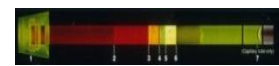

Malaria

- Devastating disease in tropical countries with 212 million cases and an estimated 429,000 deaths worldwide in 2015
- In Europe, malaria is an imported disease: returning travellers and immigrants, 6,000-10,000 per year
- Different species require different treatment/management
 - *Plasmodium falciparum*
 - *Plasmodium vivax*
 - *Plasmodium ovale (curtisi & wallikeri)*
 - *Plasmodium malariae*
 - *Plasmodium knowlesi*

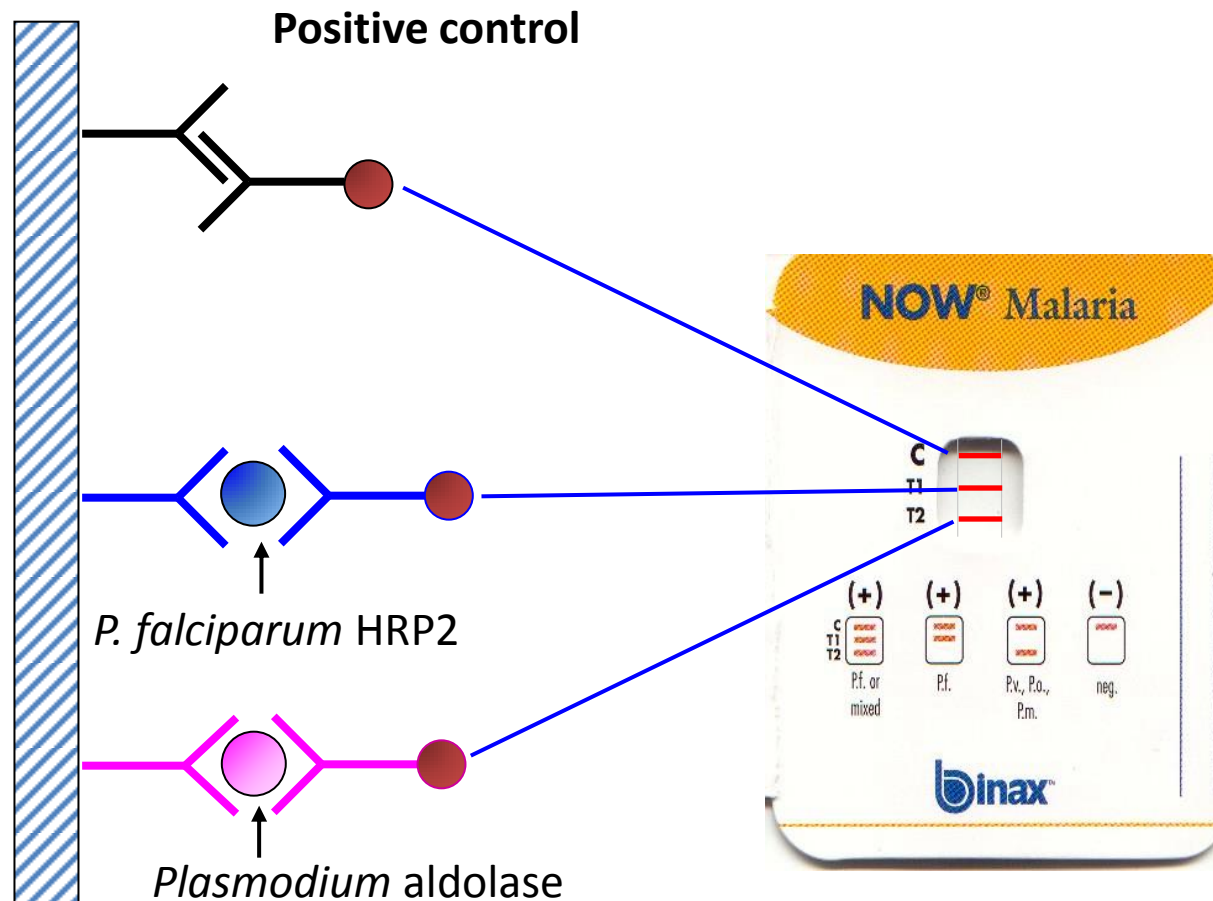


Malaria diagnosis

- Thick smear (sensitivity +++, speciation +)
- Thin smear (sensitivity ++, speciation ++)
- Quantitative buffy coat (QBC) (sensitivity +, but no speciation)
- Illumigene (LAMP) (sensitivity +++, but no speciation)
- Rapid diagnostic tests based on antigen detection (sensitivity *Pf* +++, non-*Pf* +)




Rapid Diagnostic Test (RDT): antigen detection e.g. BinaxNOW[®] Malaria



Most RDTs use HRP2 antibodies for *P. falciparum* detection

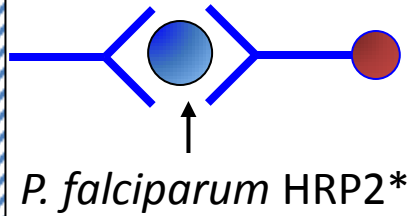
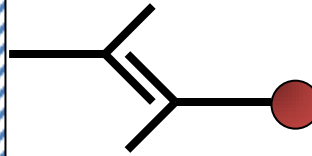
ICT Malaria Dual Test



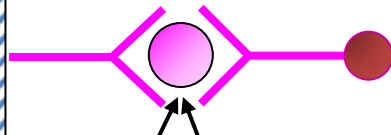
Plasmodium lactate dehydrogenase



Positive control

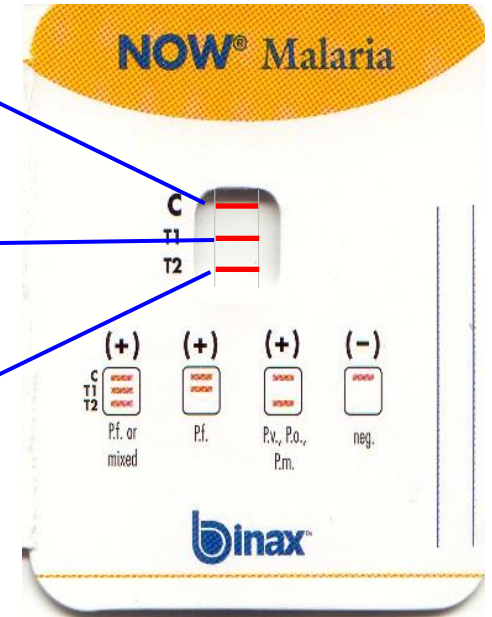


P. falciparum HRP2*



Plasmodium aldolase

BinaxNOW® Malaria



* some HRP2 antibodies cross-react with HRP3

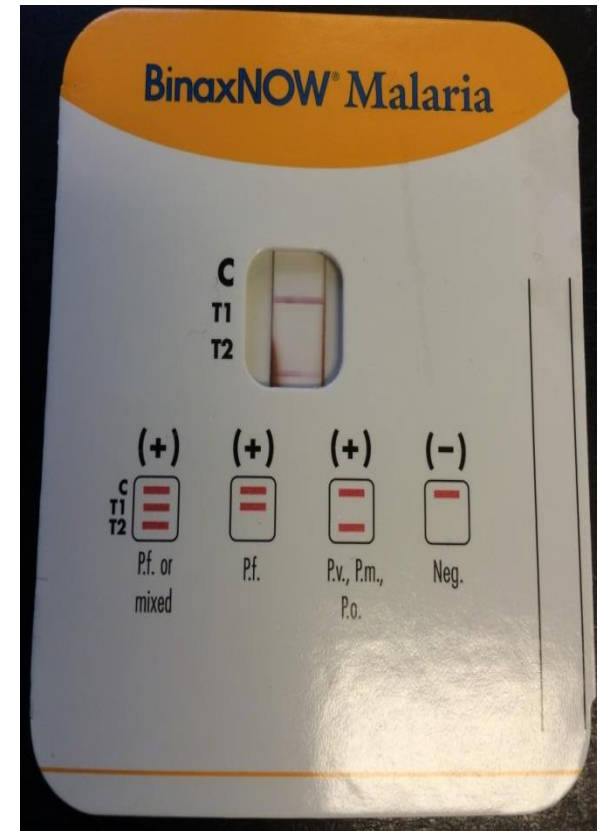
Our patient

- September 2016
- 77 year old male, living in NL, born in Eritrea, visited Eritrea for >1 month ~14 days prior to presentation
- Presented with fever

The initial tests in our patient

Malaria tests:

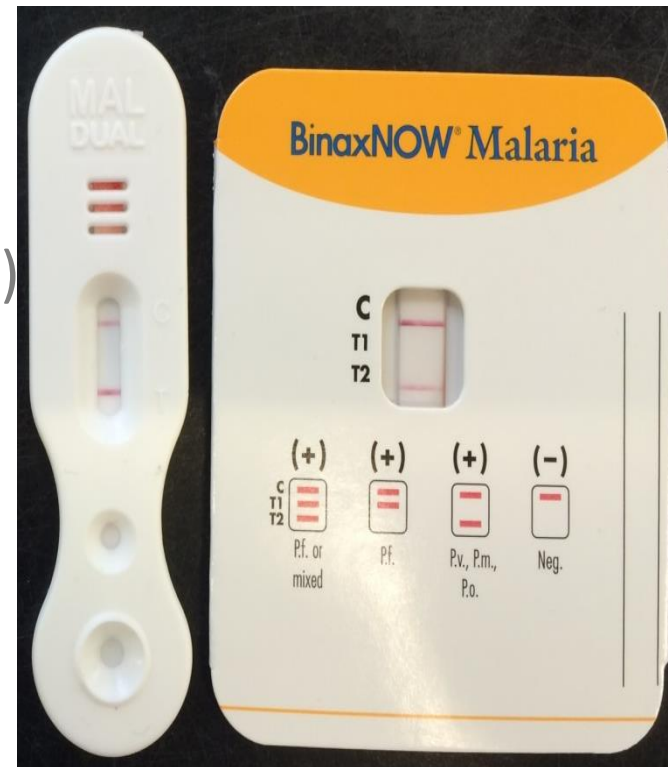
- Quantitative buffy coat: malaria parasites
- Thick smear: *P. falciparum* parasites
- Thin smear: *P. falciparum* parasites
- Parasitemia 1.6%
- RDT: BinaxNOW® Malaria: PfHRP2 (T1) negative, pan-aldolase (T2) positive



Additional tests

Malaria tests:

- Quantitative buffy coat: malaria parasites
- Thick smear: malaria parasites
- Thin smear: malaria parasites
- Parasitemia 1.6%
- RDT: BinaxNOW® Malaria: PfHRP2 (T1) negative, pan-aldolase (T2) positive
- Repeated BinaxNOW® (same results)
- Additional RDT: ICT Malaria Dual: PfHRP2 negative, pLDH positive
- Real-time PCR: *P. falciparum* DNA, Cp=30
- Illumigene® Malaria test positive



Possible causes of false negative RDT results

| Classification | Cause of false negative RDT result |
|---------------------------------|---|
| Product design or quality | Poor detection sensitivity of a RDT product due to poor specificity, affinity, or insufficient quantity of antibodies used in the RDT |
| | Poor visibility of test bands due to high background colour on the test |
| | Incorrect instructions for use |
| Transport or storage conditions | Antibody degradation due to poor durability to heat or to incorrect transport or storage |
| Operator factors | Operator error in preparing the RDT, performing the test, or interpreting the result |
| Host parasite density | Very low parasite densities/target antigen concentrations |
| | Prozone effect (hyperparasitemia/antigen overload) |
| Parasite factors | Variation in the amino acid sequence of the epitope targeted by the monoclonal antibody |
| | Parasites lacking the target antigens or expressing reduced levels of the target antigens |

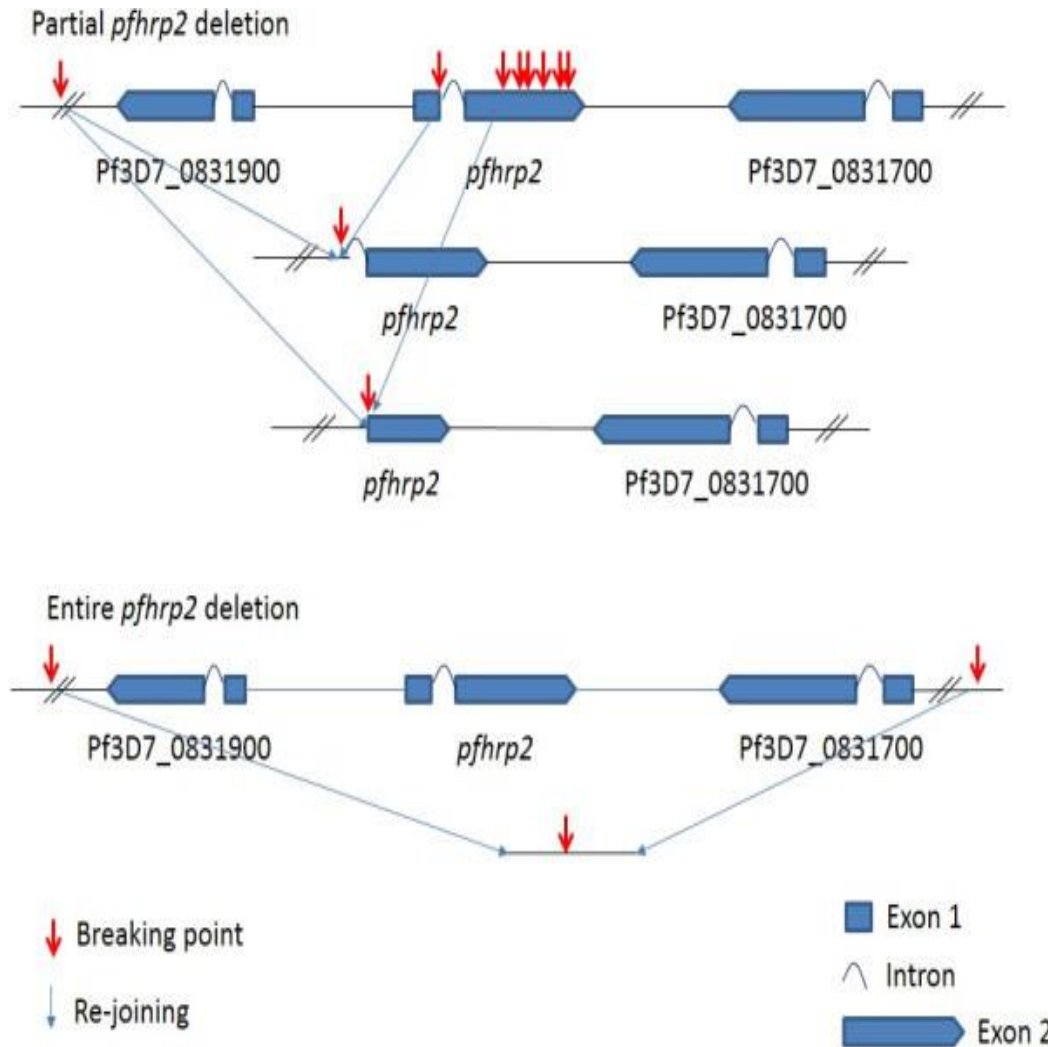
Possible causes of false negative RDT results

| Classification | Cause of false negative RDT result |
|---------------------------------|--|
| Product design or quality | <p style="text-align: center;">Excluded: other tests from the same batch by the same operator worked well, other operators obtained identical results, other RDT showed similar results</p> |
| Transport or storage conditions | |
| Operator factors | Operator error in preparing the RDT, performing the test, or interpreting the result |
| Host parasite density | Very low parasite densities/target antigen concentrations |
| | Prozone effect (hyperparasitemia/antigen overload) |
| Parasite factors | Variation in the amino acid sequence of the epitope targeted by the monoclonal antibody |
| | Parasites lacking the target antigens or expressing reduced levels of the target antigens |

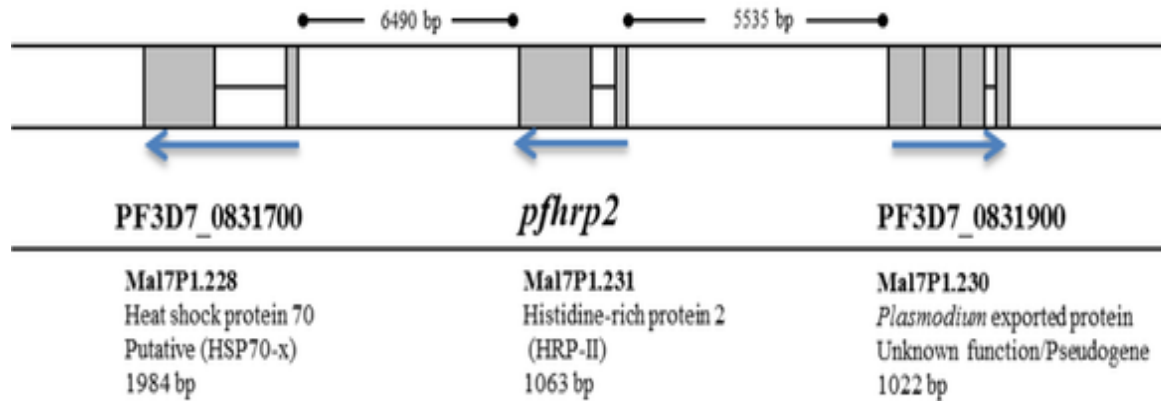
Possible causes of false negative RDT results

| Classification | Cause of false negative RDT result |
|---------------------------------|--|
| Product design or quality | <p style="text-align: center;">Excluded: other tests from the same batch by the same operator worked well, other operators obtained identical results, other RDT showed similar results</p> |
| Transport or storage conditions | |
| Operator factors | <p style="text-align: center;">Parasitemia was 1.6%: sufficient for a positive test, too low for prozone effect</p> |
| Host parasite density | Very low parasite densities/target antigen concentrations |
| | Prozone effect (hyperparasitemia/antigen overload) |
| Parasite factors | Variation in the amino acid sequence of the epitope targeted by the monoclonal antibody |
| | Parasites lacking the target antigens or expressing reduced levels of the target antigens |

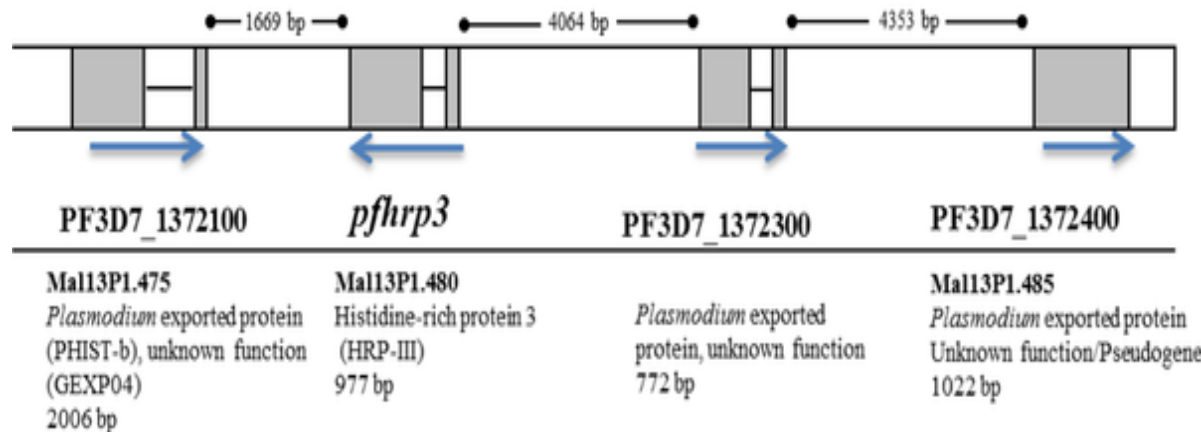
Absence of PfHRP2 and PfHRP3 in South American *P. falciparum* parasites is caused by (partial) deletion of the encoding genes



Schematic of the structure of *pfhrp2* and *pfhrp3* and their respective neighboring genes.



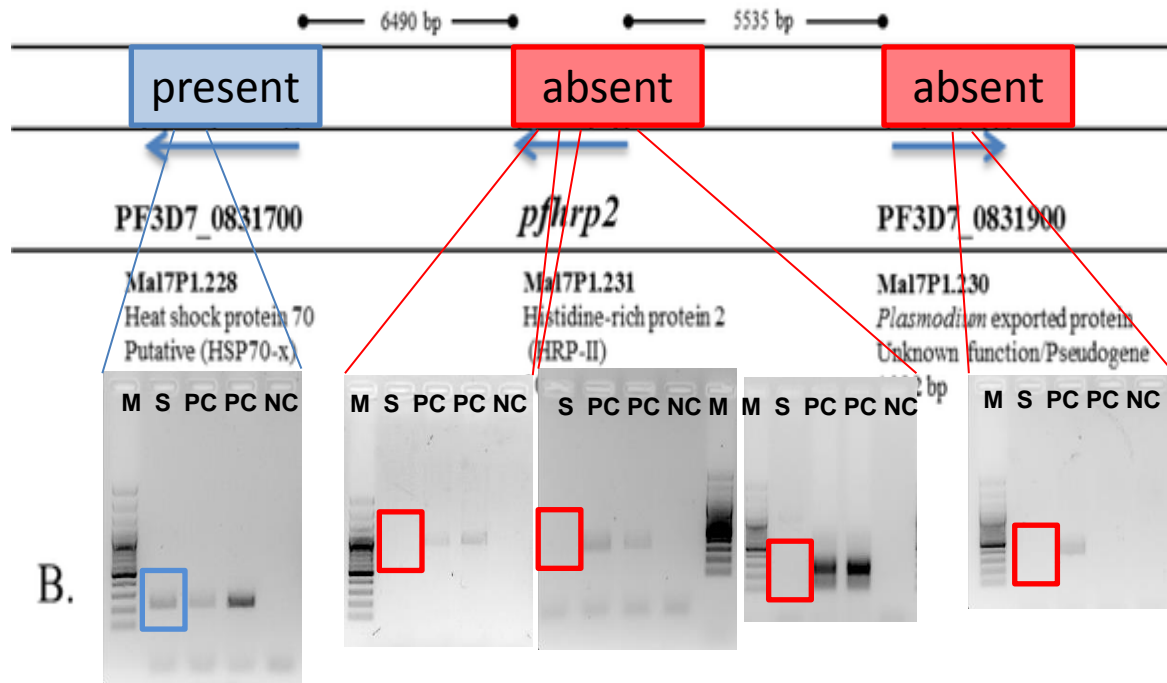
pfhrp2
locus



pfhrp3
locus

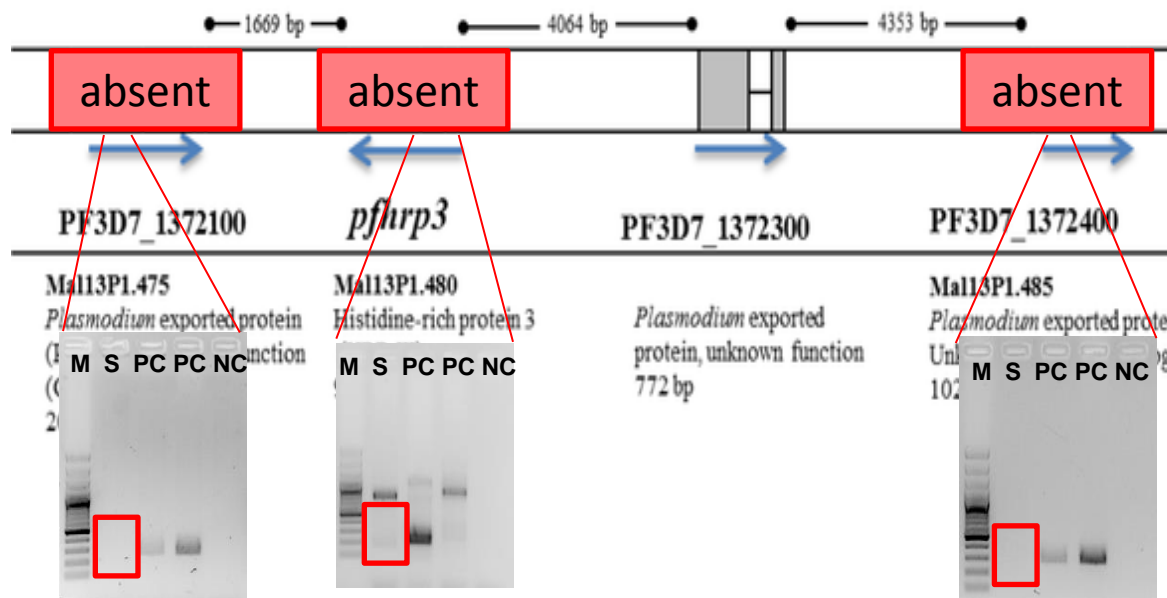
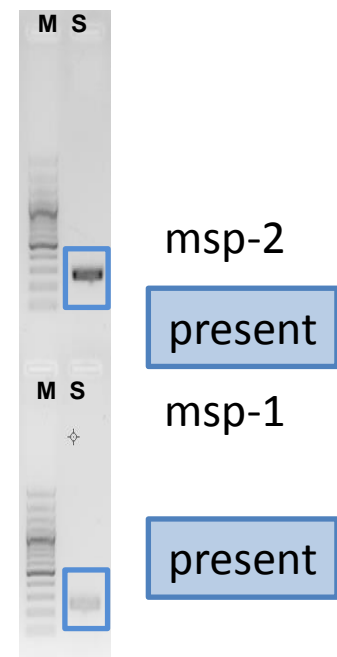
Test for presence of genes by performing (nested) PCRs for *pfhrp2* and *pfhrp3* genes and flanking regions, using similar amount of DNA from other patients as positive controls.

Schematic of the structure of *pfhrp2* and *pfhrp3* and their respective neighboring genes.



pfhrp2
locus

Control for DNA integrity and PCR amplification: 2 unrelated genomic loci



pfhrp3
locus

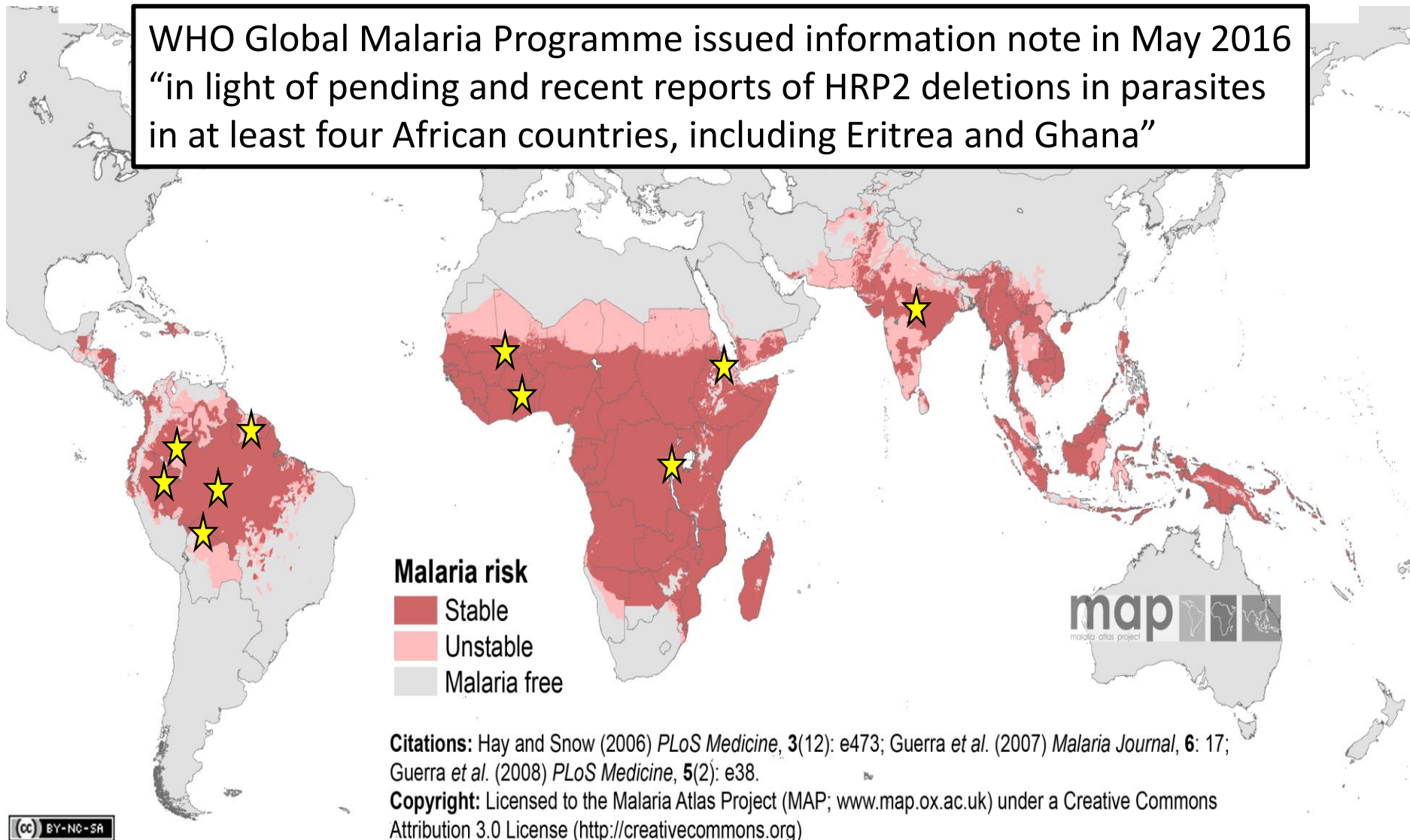
B.

Conclusion and Discussion -1-

- The *P. falciparum* from our patient from Eritrea lacks reactivity to HRP2 monoclonal antibodies in RDT due to deletion of the HRP2 and HRP3 genes
- Non-reactivity results in **false negative results** or **incorrect species assignment** in RDTs detecting both Pf HRP2 and a pan-Plasmodium antigen, which may lead to suboptimal treatment

Countries where HRP2 negative *P. falciparum* were reported

WHO Global Malaria Programme issued information note in May 2016
“in light of pending and recent reports of HRP2 deletions in parasites
in at least four African countries, including Eritrea and Ghana”



Citations: Hay and Snow (2006) *PLoS Medicine*, 3(12): e473; Guerra *et al.* (2007) *Malaria Journal*, 6: 17; Guerra *et al.* (2008) *PLoS Medicine*, 5(2): e38.

Copyright: Licensed to the Malaria Atlas Project (MAP; www.map.ox.ac.uk) under a Creative Commons Attribution 3.0 License (<http://creativecommons.org>)



★ HRP2 negative *P. falciparum* reported, prevalence up to 40%

Conclusion and Discussion -2-

- The *P. falciparum* from our patient from Eritrea lacks reactivity to HRP2 monoclonal antibodies in RDT due to deletion of the HRP2 and HRP3 genes
- Non-reactivity results in **false negative results** or **incorrect species assignment** in tests detecting both Pf HRP2 and a pan-Plasmodium antigen, which may lead to suboptimal treatment
- HRP2 negative *P. falciparum* are no longer confined to South America.
- Do not rely on HRP2 reactivity alone for *P. falciparum* detection in imported cases, keep confirming negative RDT results by microscopy or other sensitive tests (e.g. Illumigene)