





Galapagos eieren in humaan feces?

Medisch van Kuchizoyan
LabIVICTA Heragato
17 januari 2017



Patienten gegevens

- 20 jarige Nederlandse student
- Vakantie 14-07 t/m 17-8-2016, Galapagos eilanden San Cristobal, Isabela, Santa Cruz
- Stage + vrijwilligerswerk i.v.m. studie
- Heeft 14 dagen in zee water gezwommen (snorkelen)
- Inwonend bij een gastgezin
- Heeft geen rauwe groente gegeten.



2



Klachten

- 1e ziektedag 18.8.2016
- Diarree, buikkrampen, hoofdpijn, algemene malaise
- 1* week in de Galapagos gestoken door een bij of wesp

3



Diagnostiek

Parasitologisch onderzoek (DFT-set)

- Parasitologisch feces panel (*G. lamblia*, *Cryptosporidium*, *E. histolytica*)
- Wormeieren

Bacteriologisch onderzoek (ongefixeerde feces)

- Bacteriologisch feces panel
- *Clostridium difficile* toxine

Datum afname

5-9-2016
9-9-2016

4

LAB INVICTA Diagnostiek

Parasitologisch onderzoek

- Parasitologisch feces panel (*G. lamblia*, *Cryptosporidium*, *E. histolytica*)
→ NEGATIEF

Bacteriologisch onderzoek

- Bacteriologisch feces panel
- Clostridium difficile* toxine

Uitslag	Test	Uitslag
Cholera Toxine	Aur	0.06 IU/ml
Cholera Toxine ant	Aur	neg
FECCES_MLCP	Aur	Brng
Camp coli	Aur	Neg
Camp coli CP	Sp	Neg
Camp rhum	Aur	Neg
Camp rhum CP	Sp	Neg
Salm typh	Aur	Neg
Salm typh CP	Sp	Neg
Salm typh	Aur	Neg
Salm typh CP	Sp	Neg
Salm typh	Aur	Neg
Salm typh CP	Sp	Neg
Shiga toxin E.coli	Aur	POS
Shiga toxin E.coli CP	Aur	POS
Yers entero	Aur	Neg
Yers entero CP	Sp	Neg

LAB INVICTA Nat preparaat (sediment ridley)

150 um

60 um

Natpreparaat 10x [LabMKT1A]

LAB INVICTA Nat preparaat ?

150 um

60 um

Natpreparaat 10x [LabMKT1A]

130 - 150 um

60 - 90 um

Natpreparaat 10x [pic opic]

LAB INVICTA Nat preparaat

Geen Fasciola ei

Natpreparaat 40x [LabMKT1A]

Fasciola hepatica ei

Small, indistinct operculum.

Ellipsoidal, thin shell.

Natpreparaat 40x [pic opic]

Nat preparaat (sediment ridley)

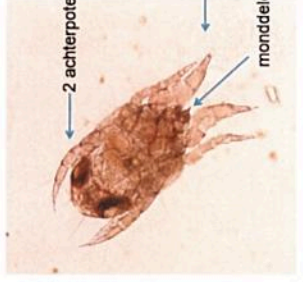


Natpreparaat, 10x (LabMictA)

9

Nat preparaat (sediment ridley)

230-300 um lang en 100-200 um breed


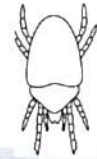


Natpreparaat, 10x (LabMictA)

10


Kenmerken

preparaat	mijten
Aantal poten	4 paar
Verdeling lichaam	2 deilig lichaam Kopborststuk Achterlijf
Verdeling achterlijf	Achterlijf, niet duidelijk verdeeld segmenten
Verdeling kopborststuk	Lichaam niet duidelijk verdeeld in kopborststuk
Afmeting	230-300 um lang 100-200 um breed
	Mijten
	<1.5 mm

11

Specialistisch determinatie boek



12

LAB
IVICTA

Mijten in feces

Table 2
A rough summary of reported cases of human infection

Species	Location	History/notes	Investigation	Diagnosis	Treatment	Ref.
<i>D. immitis</i>	USA	1957 - 1958, 1961, 1962, 1963, 1964, 1965, 1966, 1967, 1968, 1969, 1970, 1971, 1972, 1973, 1974, 1975, 1976, 1977, 1978, 1979, 1980, 1981, 1982, 1983, 1984, 1985, 1986, 1987, 1988, 1989, 1990, 1991, 1992, 1993, 1994, 1995, 1996, 1997, 1998, 1999, 2000, 2001, 2002, 2003, 2004, 2005, 2006, 2007, 2008, 2009, 2010, 2011, 2012, 2013, 2014, 2015, 2016, 2017	Microscopic examination of feces, serology, PCR	Microscopic examination of feces, serology, PCR	Antibiotics	[1, 2, 3, 4, 5, 6, 7, 8, 9, 10, 11, 12, 13, 14, 15, 16, 17, 18, 19, 20, 21, 22, 23, 24, 25, 26, 27, 28, 29, 30, 31, 32, 33, 34, 35, 36, 37, 38, 39, 40, 41, 42, 43, 44, 45, 46, 47, 48, 49, 50, 51, 52, 53, 54, 55, 56, 57, 58, 59, 60, 61, 62, 63, 64, 65, 66, 67, 68, 69, 70, 71, 72, 73, 74, 75, 76, 77, 78, 79, 80, 81, 82, 83, 84, 85, 86, 87, 88, 89, 90, 91, 92, 93, 94, 95, 96, 97, 98, 99, 100]
<i>D. immitis</i>	USA	1957 - 1958, 1961, 1962, 1963, 1964, 1965, 1966, 1967, 1968, 1969, 1970, 1971, 1972, 1973, 1974, 1975, 1976, 1977, 1978, 1979, 1980, 1981, 1982, 1983, 1984, 1985, 1986, 1987, 1988, 1989, 1990, 1991, 1992, 1993, 1994, 1995, 1996, 1997, 1998, 1999, 2000, 2001, 2002, 2003, 2004, 2005, 2006, 2007, 2008, 2009, 2010, 2011, 2012, 2013, 2014, 2015, 2016, 2017	Microscopic examination of feces, serology, PCR	Microscopic examination of feces, serology, PCR	Antibiotics	[1, 2, 3, 4, 5, 6, 7, 8, 9, 10, 11, 12, 13, 14, 15, 16, 17, 18, 19, 20, 21, 22, 23, 24, 25, 26, 27, 28, 29, 30, 31, 32, 33, 34, 35, 36, 37, 38, 39, 40, 41, 42, 43, 44, 45, 46, 47, 48, 49, 50, 51, 52, 53, 54, 55, 56, 57, 58, 59, 60, 61, 62, 63, 64, 65, 66, 67, 68, 69, 70, 71, 72, 73, 74, 75, 76, 77, 78, 79, 80, 81, 82, 83, 84, 85, 86, 87, 88, 89, 90, 91, 92, 93, 94, 95, 96, 97, 98, 99, 100]
<i>D. immitis</i>	USA	1957 - 1958, 1961, 1962, 1963, 1964, 1965, 1966, 1967, 1968, 1969, 1970, 1971, 1972, 1973, 1974, 1975, 1976, 1977, 1978, 1979, 1980, 1981, 1982, 1983, 1984, 1985, 1986, 1987, 1988, 1989, 1990, 1991, 1992, 1993, 1994, 1995, 1996, 1997, 1998, 1999, 2000, 2001, 2002, 2003, 2004, 2005, 2006, 2007, 2008, 2009, 2010, 2011, 2012, 2013, 2014, 2015, 2016, 2017	Microscopic examination of feces, serology, PCR	Microscopic examination of feces, serology, PCR	Antibiotics	[1, 2, 3, 4, 5, 6, 7, 8, 9, 10, 11, 12, 13, 14, 15, 16, 17, 18, 19, 20, 21, 22, 23, 24, 25, 26, 27, 28, 29, 30, 31, 32, 33, 34, 35, 36, 37, 38, 39, 40, 41, 42, 43, 44, 45, 46, 47, 48, 49, 50, 51, 52, 53, 54, 55, 56, 57, 58, 59, 60, 61, 62, 63, 64, 65, 66, 67, 68, 69, 70, 71, 72, 73, 74, 75, 76, 77, 78, 79, 80, 81, 82, 83, 84, 85, 86, 87, 88, 89, 90, 91, 92, 93, 94, 95, 96, 97, 98, 99, 100]

Ref: 1. Journal of Clinical Microbiology, 1957; 2. Journal of Clinical Microbiology, 1958; 3. Journal of Clinical Microbiology, 1961; 4. Journal of Clinical Microbiology, 1962; 5. Journal of Clinical Microbiology, 1963; 6. Journal of Clinical Microbiology, 1964; 7. Journal of Clinical Microbiology, 1965; 8. Journal of Clinical Microbiology, 1966; 9. Journal of Clinical Microbiology, 1967; 10. Journal of Clinical Microbiology, 1968; 11. Journal of Clinical Microbiology, 1969; 12. Journal of Clinical Microbiology, 1970; 13. Journal of Clinical Microbiology, 1971; 14. Journal of Clinical Microbiology, 1972; 15. Journal of Clinical Microbiology, 1973; 16. Journal of Clinical Microbiology, 1974; 17. Journal of Clinical Microbiology, 1975; 18. Journal of Clinical Microbiology, 1976; 19. Journal of Clinical Microbiology, 1977; 20. Journal of Clinical Microbiology, 1978; 21. Journal of Clinical Microbiology, 1979; 22. Journal of Clinical Microbiology, 1980; 23. Journal of Clinical Microbiology, 1981; 24. Journal of Clinical Microbiology, 1982; 25. Journal of Clinical Microbiology, 1983; 26. Journal of Clinical Microbiology, 1984; 27. Journal of Clinical Microbiology, 1985; 28. Journal of Clinical Microbiology, 1986; 29. Journal of Clinical Microbiology, 1987; 30. Journal of Clinical Microbiology, 1988; 31. Journal of Clinical Microbiology, 1989; 32. Journal of Clinical Microbiology, 1990; 33. Journal of Clinical Microbiology, 1991; 34. Journal of Clinical Microbiology, 1992; 35. Journal of Clinical Microbiology, 1993; 36. Journal of Clinical Microbiology, 1994; 37. Journal of Clinical Microbiology, 1995; 38. Journal of Clinical Microbiology, 1996; 39. Journal of Clinical Microbiology, 1997; 40. Journal of Clinical Microbiology, 1998; 41. Journal of Clinical Microbiology, 1999; 42. Journal of Clinical Microbiology, 2000; 43. Journal of Clinical Microbiology, 2001; 44. Journal of Clinical Microbiology, 2002; 45. Journal of Clinical Microbiology, 2003; 46. Journal of Clinical Microbiology, 2004; 47. Journal of Clinical Microbiology, 2005; 48. Journal of Clinical Microbiology, 2006; 49. Journal of Clinical Microbiology, 2007; 50. Journal of Clinical Microbiology, 2008; 51. Journal of Clinical Microbiology, 2009; 52. Journal of Clinical Microbiology, 2010; 53. Journal of Clinical Microbiology, 2011; 54. Journal of Clinical Microbiology, 2012; 55. Journal of Clinical Microbiology, 2013; 56. Journal of Clinical Microbiology, 2014; 57. Journal of Clinical Microbiology, 2015; 58. Journal of Clinical Microbiology, 2016; 59. Journal of Clinical Microbiology, 2017.

LAB
IVICTA

Determinatie kenmerken

Tarsus →

← Geen claw as a clomb

Nabeparaat, 40x [Lab/McTA]

14

LAB
IVICTA

Determinatie kenmerken

Apodemes joined

Palp= Paired sensory mouth parts

Chelicera = feeding mouth parts

Monddelen zijn kort

Nabeparaat, 40x [Lab/McTA]

15

LAB
IVICTA

Determinatie kenmerken

Posterior setae = Elongate hairs


Copulatory sucker = Male structures for holding the female mite

Coxa = Basal leg structure.

Nabeparaat, 40x [Lab/McTA]

16

Nat preparaat



Natpreparaat 40x [LabMicta]

17

Overige kenmerken mijt

	preparaat
Voorpoten	Geen grote pulvilli (kussens)
Achterpoten	Geen claspings (voor het aanhechten a.d. haren van de gastheer)
Monddelen	Kort
Apodemes	Joined, Y- vormig
Vorm	Onregelmatig ovaal
Posterior end	2 lange setae
Onderlijf	Niet Striated (gegroefd)

18

Overleg



Kennis- en Adviescentrum Dierplagen

Suidasia mites + eieren

19

Storage mites

Super family	Family	Genus	Species	
Storage mites	Glycyphagidae	Acarodes	Chortophagus	C. armatus
			Edonyphagus	E. rufipes
			Amegophagus	G. melleipes
			Glycyphagus	G. fulvus
			Glycyphagus	G. obscurus
			Lepidophagus	L. domus
			Troglyphidae	A. sp.
			Troglyphus	T. phoeniceus
			Acarozobidae	A. larrea
			Suidasia	S. sulim
			Suidasia	S. westringii
			Laelophagidae	L. turkii
		L. bovei		

Bron: **When mites attack: domestic mites are not just allergens**

20

Behandelende patiënt?

Author	Location	Study species	Program	Treatment	Ref.
Wang et al.	China	<i>Tyroglyphus longior</i>	Condition for health education for the household	Hygiene education	[1]
Wang et al.	China	<i>Tyroglyphus longior</i>	Condition for health education for the household	Hygiene education	[2]
Wang et al.	China	<i>Tyroglyphus longior</i>	Condition for health education for the household	Hygiene education	[3]
Wang et al.	China	<i>Tyroglyphus longior</i>	Condition for health education for the household	Hygiene education	[4]
Wang et al.	China	<i>Tyroglyphus longior</i>	Condition for health education for the household	Hygiene education	[5]
Wang et al.	China	<i>Tyroglyphus longior</i>	Condition for health education for the household	Hygiene education	[6]
Wang et al.	China	<i>Tyroglyphus longior</i>	Condition for health education for the household	Hygiene education	[7]
Wang et al.	China	<i>Tyroglyphus longior</i>	Condition for health education for the household	Hygiene education	[8]
Wang et al.	China	<i>Tyroglyphus longior</i>	Condition for health education for the household	Hygiene education	[9]
Wang et al.	China	<i>Tyroglyphus longior</i>	Condition for health education for the household	Hygiene education	[10]

From: <http://www.ncbi.nlm.nih.gov/pmc/articles/PMC4158066/>

Bronnen

Arthropods of humans and domestic animals, a guide to preliminary identification, Alan Walker, 1984

Determinatie Dictaat KAD

Medical and veterinary entomology, Mites borne diseases of humans, 443, G. Muller

When mites attack: domestic mites are not just allergens

Take home message

Intestinal acariasis

Intestinal acariasis is caused by ingestion of mite-contaminated foods. This invasion of the human gastrointestinal tract can cause symptoms including diarrhea, abdominal pain, and burning sensation around the anus. The first case of intestinal acariasis was reported by Hirman & Kammerer [36], who detected *Tyroglyphus longior* (Tyroglyphidae) in human intestine [36]. Three cases of intestinal acariasis were described in Spain, one of these was *Suidasia mites* [37]. Several cases of diarrhea were reported caused by *Carapoglyphus laevis*, presumed to have been transmitted through contaminated imported sugar [14, 38]. Other studies have identified cases of abdominal pain, diarrhea, fatigue, and pyrometolacta attributable to *Dermatophagoides fariniae*, *D. pteronyssinus*, *Acarus saro*, *Tyropiagopus pluriscentiae*, *Carapoglyphus domesticus*, *Glycyptopus domesticus*, *G. privatus*, and *Tarsonemus granarius* [39–41]. Interestingly, an allergic intestinal acariasis syndrome has also been described [42]. **Occasionally mite eggs, rather than (or in addition to) mites, have been found in stools [43, 44]. Indeed, Wernick et al. indicated that stool samples containing mite eggs, which were sometimes accompanied by adult mites, may often be misidentified as helminth ova, leading to erroneous treatment with far-reaching consequences [44].**

Both direct fecal smear and a saturated salt solution floating method can be used for detection of mites in larva, adult, live, dead, or egg stage. Zhang et al. developed an avidin-biotin system enzyme-linked immunosorbent assay (ABC-ELISA) to aid diagnosis of intestinal acariasis [45]. Further, Li [46] suggested the broad-spectrum antiparasitic drug ivermectin as the first choice for treatment of human intestinal acariasis [46].

Bron: <http://www.ncbi.nlm.nih.gov/pmc/articles/PMC4158066/>

Lab MICTA

Samen tegen infecties

www.labmicta.nl